



Original Research Article

MORPHOMETRIC STUDY OF ADULT DRY HUMERI OF SOUTH INDIA AND ITS IMPORTANCE IN FORENSIC PRACTICE

Ravindra Halkai¹, Syeda Sadia Sameera², Basavaraj Patil³

¹Associate Professor, Department of Forensic Medicine, M.R. Medical College, Kalaburagi, India.

²Professor, Department of Anatomy, Maheswara Institute of Medical Sciences, Patancheru, Sangareddy District, Telangana.

³Professor and HOD, Department of Forensic Medicine, M.R. Medical College, Kalaburagi, India.

Received : 14/09/2024
Received in revised form : 03/11/2024
Accepted : 17/11/2024

Corresponding Author:

Dr. Basavaraj Patil,
Professor and HOD, Department of
Forensic Medicine, M.R. Medical
College, Kalaburagi, India.
Email: bspatil1210@ gmail.com

DOI: 10.70034/ijmedph.2024.4.140

Source of Support: Nil,
Conflict of Interest: None declared

Int J Med Pub Health
2024; 14 (4); 750-753

ABSTRACT

Background: The humerus is the long bone of the upper arm. Given that the head of the humerus articulates with the glenoid cavity of the shoulder joint, the humerus is crucial for abduction of the arm and thus the basic motion of lifting the arm. Despite its crucial function, the humerus remains one of the most commonly fractured bones in the body. These fractures typically either occur due to blunt trauma or pathologic risk factors, such as metastatic bone diseases or osteoporosis. The morphometric study of humeral bone is of great importance, given its clinical significance and in forensic practice to estimate length of long bones.

Materials and Methods: The present study was conducted with 74 dry adult human humeri. For measuring humerus, we have used anthropometric board and vernier clippers was used for measuring segments. Each humerus was studied for the humerus segmental morphometric analysis. In present study we have measured segments of humeri and length of humeri.

Results: Out of 74 humeri 44 were right and 30 were left. We found, maximum length of humerus was 304.2±24.3mm on right and left was 302.84±22.6mm. there was no significant difference between measurements of segments of right and left humeri. All the measurements were analysed and expressed in Mean±SD.

Conclusion: The present study findings may be helpful in practice of forensic medicine, anthropology and orthopaedic surgeons. Humeral bone knowledge may be helpful to understand fractures and surgeries in should regions for clinicians.

Keywords: Humerus, Head of Humerus, Shoulder joint, Fracture of humerus.

INTRODUCTION

The humerus is the longest and largest bone of the upper limb and it is very important to identify the humeral length from the segmental measurements. Anthropometric techniques have been commonly used to estimate stature and bone length from the skeletal remains and unknown body parts by anthropologists, medical scientists and Anatomists for over a hundred years. In the absence of the bones of skeleton, long bone with intact ends can be overcome by applying the derived method to the available fragment of bone. This will help to solve medico legal problems giving due consideration to

regional factors. The estimation of the skeletal samples of the burials is often fragmentary and are found in mixed lots.^[1,2,3]

Estimating of stature from bones play an important role in identifying unknown bodies, parts of bodies or skeletal remains. Anthropometric techniques have been commonly used to estimate stature and bone length from the skeletal remains and unknown body parts by anthropologists, medical scientists and anatomists for over a hundred years. Statures estimated from the human skeletal remains is an important step in assessing health and general body size trends among the given populations and also have an important role in the identification of

missing persons in to medico-legal investigations. In the absence of pelvis and cranium, morphometric analysis is frequently carried out on the remains of the long bones of the individual in anthropology and forensic science investigations and femur and tibia of the lower limb collectively remains the best for the assessment of living stature of the individual. However in their absence, estimation of living stature can also be done from the long bones of the upper limb viz. Humerus, radius and ulna. For this purpose, either humerus can be used alone or collectively with other bones of upper limbs for the determination of sex and the estimation of stature of an individual.^[4,5] The estimation of bone length from incomplete long bones was firstly identified by Müller. She defined 5 segments for the humerus using the margins of articular surfaces and key points of muscle attachment.^[6] Proximal humeral fractures are common injuries. They occur along the physal lines of the proximal humerus and within its segments. Soft tissue attachments including the insertions of the rotator cuff tendons and the deltoid, pectoralis major, latissimus dorsi and teres major muscles can cause displacement of the various parts in proximal humeral fractures and likewise isolated displaced fractures of the greater tuberosity.^[7,8] The present study was conducted to find out the morphometric analysis of humerus segments, which may be helpful to forensic experts and anthropologists.

MATERIALS AND METHODS

The present study was conducted with 74 dry adult human humeri. The Humeri were collected with medical students and anatomy and forensic medicine, departments of MRMC, Kalaburagi, Karnataka. We have chosen clean and unbroken humeri for study. We have excluded humeri with deformity, damaged and broken bones for study. For measuring humerus, we have used anthropometric board and vernier clippers was used for measuring segments. Each humerus was studied for the humerus segmental morphometric analysis. In present study we have measured following measurements. All the measurements were analysed and expressed in Mean±SD. SPSS 16 was used to analyse the data. The measurements includes, Maximum length of humerus, Mean distances between the articular segment of the humeral head and the greater tuberosity of humerus, Mean distance between caput humerus and callum of humerus, Mean distance between proximal and distal point of olecrane of humerus, Mean distance between distal part of olecrane process and trochlea of humerus, Mean distance between proximal edge of olecrane fossa and proximal part of trochlea of humerus. [Figure 1].



Figure 1: Humeri Collected for study

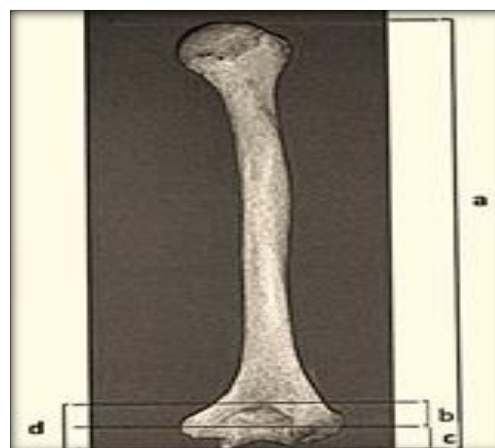


Figure 2: Marking of segments of humeri,^[11]

a) Maximum length of humerus, b) Distance between proximal and distal edge of olecranon fossa, c) Distance between distal edge of olecranon fossa and trochlea, d) Distance between proximal edge of olecranon fossa and distal edge of trochlea.

RESULTS

In present study we used 74 humeri, we have measured the following measurements with help of anthropometric board and vernier callipers. Out of 74 humeri 44 were right and 30 were left. We found, maximum length of humerus was 304.2 ± 24.3 mm on right and left was 302.84 ± 22.6 mm. The mean distances between the articular segment of the humeral head and the greater tuberosity was 7.7 ± 1.2 mm on right and 7.2 ± 0.9 mm on left. The mean distances between caput humerus and callum anatomicum was 42.1 ± 4.8 mm on right and 40.9 ± 6.6 mm on left. The mean distances between proximal and distal point of olecrane fossa was 40.2 ± 1.9 mm on right and 41.6 ± 2.3 mm on left. The mean distances between distal part of olecrane process and trochlea of humerus was 23.8 ± 3.2 mm on right and 24.6 ± 1.6 mm on left. The mean distances between proximal edge of olecrane fossa and proximal part of trochlea of humerus was 24.42 ± 2.6 mm on right and 23.24 ± 1.9 mm on left.

Table 1: Morphometric measurements of Humerus segments

S. No	Measurement	Right (mm)	Left (mm)
1	Maximum length of humerus	304.2±24.3	302.84±22.6
2	The mean distances between the articular segment of the humeral head and the greater tuberosity	7.7±1.2	7.2±0.9
3	The mean distances between caput humerus and callum anatomicum	42.1±4.8	40.9±6.6
4	The mean distances between proximal and distal point of olecrane fossa	40.2±1.9	41.6±2.3
5	The mean distances between distal part of olecrane process and trochlea of humerus	23.8±3.2	24.6±1.6
6	The mean distances between proximal edge of olecrane fossa and proximal part of trochlea of humerus	24.42±2.6	23.24±1.9

DISCUSSION

The humerus forms the skeleton of the arm and articulates proximally at the shoulder joint with the scapula and distally at the elbow joint with the radius and ulna. It is a long bone consisting of a proximal rounded head, a shaft and an irregular distal end. The head, which faces medially and slightly posteriorly, forms almost a third of a sphere and is separated from the rest of the bone by the anatomical neck, to which the greater part of the capsule of the shoulder joint is attached. In morphometric examinations, involving all around saved bones of the human body as far as anthropological data is vital. Other than the bone design of the pelvis and noggin, humerus, tibia, femur, sternum, ulna, bone, calcaneus, span bones are additionally utilized in anthropological examinations. Because of the bone distortions framed because of substance and mechanical variables, the utilization of strong bones, for example, humerus has become extremely normal for the sex assurance. In this way, humerus has been oftentimes involved by specialists in criminological and anthropological examinations. In accordance with this information, the point of our review is to perform morphological estimations of humerus segments.^[1,6,9,10,11]

In present study out of 74 humeri 44 were right and 30 were left. We found, maximum length of humerus was 304.2±24.3mm on right and left was 302.84±22.6mm. we have mentioned all the segments measurements in table format. [Table 1] Srivastava, R. K,^[9] study reported the mean length of humerus on left side is 290.2 and 291.02 on right side. The mean of the transverse diameter of humeral head is 39.53 mm and left side is 36.99 m. The mean vertical diameter of humeral head with respect to lateral-medial direction on right side is 41.63mm and on the left side is 38.89mm. The mean of highest point of humeral head and greater tubercle on right side is 7.24mm and on the left side is 6.25mm. The study of Shaziya Afzal et al,^[12] with 70 dry adult humeri reported the average maximal length of the humerus the right side was 306.55±16.45mm and on the left side was 303.20±11.12mm. The transverse distance between the medial and lateral epicondyle on the right side of the humerus was 59.47±2.53mm and on the left side 57.57±3.53mm. The average transverse distance between the capitulum and medial flange of trochlea on the right side was 42.27±1.99mm and on the left

side is 42.48±2.42mm respectively. The average maximum transverse distance from the medial epicondyle to the capitulum on the right side was 56.60±2.71mm and on the left side was 53.95±3.96. The average maximal horizontal diameter of trochlea on the right side was 23.27±1.79 and on the left side was 22.80±1.74. The anteroposterior diameter of the trochlea at the middle of the trochlea on the right side was 16.57 ±1.55 and on the left side was 16.30±1.24 respectively. The maximal length of the medial flange of the trochlea on the right side was 23.23±1.67 and on the left side was 22.67±1.70. The maximal length of the lateral flange of the trochlea on the right side was 18.17±1.72 and on the left side was 17.17±1.28 respectively. According to Vinay, G et al,^[13] study the average value of the maximal length of the arm bone in the present study was 306.3 ± 21.19 mm in the right humerus and 301.1 ± 22.4 mm in the left humerus.

In Zarana A,^[14] study, observed that mean values of the total humerus length is 30.32 ± 1.58 cm and 30.39 ± 1.66 cm on the left and right side respectively. Horizontal distance from medial epicondyle to lateral epicondyle was 5.66 ± 0.36 and 5.58 ± 0.42 cm on right and left side respectively; Horizontal distance from medial margin of trochlea to capitulum was 3.87 ± 0.25 and 3.90 ± 0.30 cm on right and left side respectively; Maximum transverse diameter of trochlea was 2.26 ± 0.18 & 2.24 ± 0.20 cm on right and left side respectively; Horizontal distance from medial epicondyle to capitulum was 5.42 ± 0.33 and 5.39 ± 0.41 cm on right and left side respectively; Anteroposterior diameter of the trochlea was 1.45 ± 0.15 and 1.45 ± 0.17 cm on right & left side respectively.

Rai, R.K., & Chawla, M,^[15] study measured maximum length of humerus (MHH), distance between articular segment of humerus head and greater tuberosity (H1), caput humeri and collum anatomicum (H2), proximal and distal point of olecranon fossa (H3), distal point of olecranon fossa and trochlea humeri (H4) and proximal edge of olecranon fossa and proximal point of trochlea humeri (H5). And they found the mean MHH, H1, H2, H3, H4 and H5 were found to be 302±2.14mm, 6.4±1.3mm, 39.3±5.4mm, 27.4±2.4mm, 26.1±2.1 and 34.5±6 on the right and 297.5±2.1mm, 6.5±1.3mm, 39.2±4.8mm, 27.5±2.6mm, 22.1±2.3 and 32.6±3.5mm on the left humerus respectively.

CONCLUSION

The morphometric analysis of the humerus segments can be useful for anatomists, forensic experts, and archaeologists for the estimation of the stature, age, and sex of an individual. This information is also useful for surgeons in preparing implants and reconstruction of fractures of the distal end of the humerus.

REFERENCES

1. Niraj Pandey, Anusuya Shrestha, Gopal KC, Nitasha Sharma, Laxmi Bhattarai, Ram Prakash Shah. Morphometric Measurements of Humerus Segments. Seed Foundation Health Journal. 2018;2(2).
2. Ozaslan A, İşcan MY, Ozaslan I, Tugcu H, Koc S. Estimation of stature from body parts. Forensic science international. 2003;12;132(1):40-5.
3. Dan U, Mukhopadhyay PP, Ghosh TK, Biswas S. Estimation of stature from fragment of long bone (tibia) in Indian Bengali population J. AnatSoc India. 2009;58(2):169-72.
4. Nc, P., Shivashankarappa, A., Havaladar, P.P., Bn, S., & Saheb, S.H. (2017). A study on segments of humerus and its clinical importance. International Journal of Orthopaedics Sciences, 3, 752-754.
5. Ross AH Konigsberg LW. New formulae for estimating stature in the Balkans. J. Forensic Sci. 2002; 47(1)165-7. 2.
6. Wright LE, Vásquez MA. Estimating the length of incomplete long bones: Forensic standards from Guatemala. Am. J. Phys. Anthropol. 2003;120(3):233-51.
7. Akman SD, Karkas P, Bozkir MG. The morphometric measurements of humerus segments Turk J Med Sci. 2006; 36:81-5.
8. Desai, S. D. & Shaik, H. S. A morphometric study of humerus segments. J.Pharm. Sci. Res., 4(10):1943-5, 2012.
9. Srivastava, R. K. "Morphometric Study of Proximal End of Humerus in North Indian Population. Journal of Medical Science and clinical Research. 2020. DOI:10.18535/jmscr/v8i8.19.
10. Khaleel N, Hussain Saheb Shaik, Osteometric study of human femur, International Journal of Research in Medical Sciences. 2014;2(1):104.
11. Sanjeev Kumar Sinha, Sanjay Kumar, Margaret Roshni Dhan, Vinod kumar. Morphometric study of segments of humerus in population of bihar. Int J Anat Res 2020;8(1.1):7217-7220. DOI: 10.16965/ijar.2019.342.
12. Shaziya Afzal, Sabia Nazir, Javed Ahmad Khan, Mohd Arif Makdoomi, Ghulam Mohammad Bhat, S M Muhallil, & Sajad Hamid. (2024). Morphometric study of the distal end of the dry adult humerus and its clinical correlation: an institutional study. Journal of Population Therapeutics and Clinical Pharmacology, 31(2), 872-878.
13. Vinay, G.; Benjamin, W.; Das, Aditya K; Raviprasanna, K. H.; Kumar, D Sunil. Morphometric Study of the Distal end of Dry Adult Humerus of the South Indian Population with Its Clinical Applications. National Journal of Clinical Anatomy 10(2):p 70-74, Apr-Jun 2021. | DOI: 10.4103/NJCA.NJCA_53_20.
14. Zarana A. Ashiyani, Seema Solanki, C. D. Mehta. The Morphometric Measurement of Segments of Humerus. J Res Med Den Sci 2016;4(1):38- 40.
15. Rai, R.K., & Chawla, M. Morphometry of adult humerus bone in Moradabad region. International Journal of Biomedical and Advance Research. 2014;5, 163-165. DOI:10.7439/IJBAR.V5I3.713.